

## **Iris and Chorioretinal Coloboma with Bilateral Congenital Cataract: A Case Report**

Kouisbahi.A ; Mouine.S ; Elorch.H ; Ibrahimi.F ; Oudbib M; Berraho.A  
*Service d'ophtalmologie B, hôpital des spécialités, CHU de Rabat, quartier Souissi, 6220 Rabat, Maroc*  
\*Corresponding Author: Kouisbahi.A

Date of Submission: 21-07-2018

Date of acceptance: 12-08-2018

### **I. Introduction**

Ocular coloboma is a rare eye malformation due to faulty closure of the embryonic fissure, which normally occurs in the sixth and seventh weeks of fetal development. Coloboma may involve various parts of the eye, including the iris, lens, ciliary body, choroid, retina, and optic nerve. Classic defects include the absence of the inferior quadrant of the iris, choroid, and retina [1,2]. Associated ophthalmologic manifestations can include cataract, microcornea, nystagmus, optic atrophy, and retinal detachment [3].

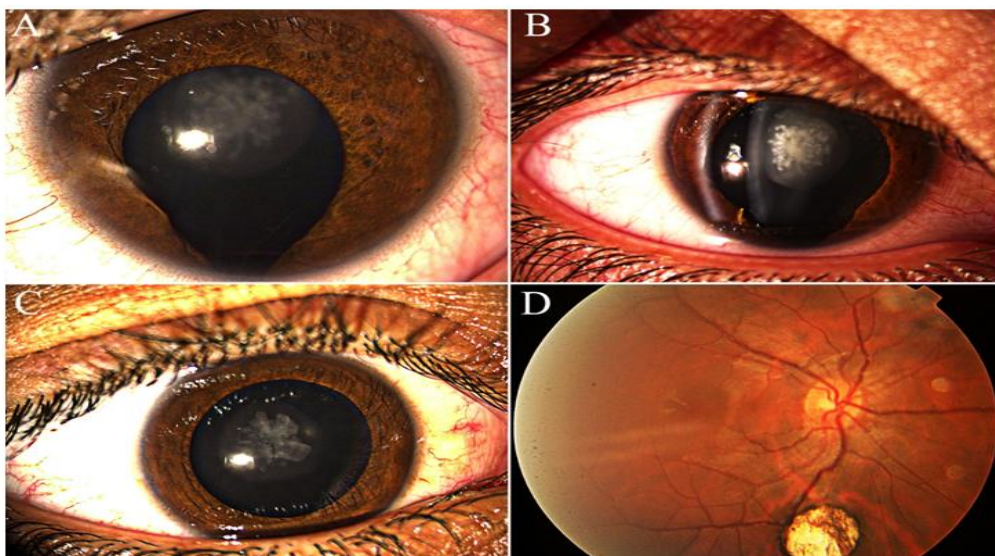
We report here a case of iris and chorioretinal coloboma with bilateral congenital cataract.

### **II. Clinical Case**

An eight-year-old boy was referred to our ophthalmology service due to abnormal visual acuity test at school. He was a well-developed boy with undistinguished systemic disease. There was no other ocular or systemic symptoms, history of trauma, and no similar cases in other members of family. His best corrected visual acuity (BCVA) was 1/10 in the right eye and 2/10 in the left eye.

Biomicroscopic examination of the right eye revealed iris coloboma in the inferior quadrant, and nuclear congenital cataract (Fig 1A, 1B). In the left eye, there was a nuclear congenital cataract (Fig 1C) but the iris was normal, there was no lens coloboma, phacodonesis or lens subluxation. The examination of the fundus evidenced a 2-disc-sized chorioretinal coloboma inferior to the papilla in the right eye (Fig 1D), no retinal detachment was found, and the bilateral maculae were normal. Intraocular pressures were normal. The rest of the ophthalmological examination was normal. A systemic assessment looking for other malformations, especially cardiac, neurological or genital, was normal.

In both eyes, congenital cataract was removed by lens phaco- aspiration, posterior capsulorhexis and anterior vitrectomy was performed to prevent posterior capsular or anterior hyaloid opacity, and intracapsular placement of Intraocular Lens (IOL) was made. The iris coloboma was repaired by pupilloplasty technique. The BCVA after operation and occlusion therapy improved significantly in both eyes.



**Figure 1:** iris coloboma and nuclear cataract in the right eye (A, B); nuclear cataract in the left eye (C); 2-disc-sized chorioretinal coloboma inferior to the papilla in the right eye (D)

### **III. Discussion**

Ocular coloboma is found in 7 per 100 000 births and its incidence is 1 of 40 ocular anomalies in the literature [3]. It can happen after a single gene abnormality or be part of a multisystem disorder with unknown etiology. Inheritance patterns are usually autosomal dominant; however, they can be autosomal recessive or sporadic [2]. Risk factors in coloboma development include older paternity age, history of prematurity or low birth weight and alcohol consumption of mother in pregnancy [5].

A complete iris coloboma is a full thickness defect, involving the pigment epithelium and the iris stroma. It can be total, extending to the iris base and giving the “keyhole pupil” aspect, or partial, involving only the pupillary edge [4]. Although isolated cases of iris coloboma are observed, it is often associated with others ocular colobomas.

A coloboma of the choroid is characterized by congenital absence of part of the retinal pigment epithelium and choroid. Typically it appears as a prominent white zone within the ocular fundus, usually in the inferonasal quadrant. The lesion consists of a rudimentary retina with a few blood vessels over the sclera, which may be ectatic [1]. Visual prognosis is dependent on the size and extent of the choroidal coloboma, associated ocular anomalies, and the risk of rhegmatogenous retinal detachment [6,7]. Bilateral cases can be a part of CHARGE syndrome (Colobomas, Heart Defects, Atresia, Retardation of Growth and Ear abnormalities) [8]. In our case only congenital cataract was associated to iris and choroidal colobomas. In systemic examination no other abnormality was seen.

Cataract surgery in eyes with coloboma can present intraoperative difficulties and high risk of complications because of the associated ocular malformations. There may be associated scleral weakness, zonular deficiency, poor pupillary dilatation and accompanied microphthalmos. In addition, these eyes are to be manipulated with prudence due to the increased risk of retinal detachment, association of maculopathy and poor surgical results [9].

### **IV. Conclusion**

There is wide variation in severity of ocular involvement in coloboma cases, ranging from a small iris coloboma to a defect that causes severe visual impairment. Coloboma cases should be carefully examined for other systemic or ocular abnormalities, and proper treatment depending on location and severity should be performed.

### **Compliance with Ethical Standards**

All authors declare that he/she has no conflict of interest.

### **References**

- [1]. Uhumwangho OM, Jalali S. Chorioretinal coloboma in a paediatric population. *Eye (Lond)*. 2014 Jun;28(6):728-33.
- [2]. Pagon RA. Ocular coloboma. *Surv Ophthalmol* 1981; 25: 223–236.
- [3]. Mohamed A, Chaurasia S, Ramappa M, Sangwan VS. Lenticular changes in congenital iridolenticular choroidal coloboma. *Am J Ophthalmol*. 2014 Oct;158(4):827- 830.
- [4]. Benjamin C. Onwochei, John W. Ocular Colobomata. Major review survey of ophthalmology. Volume 45, Number 3. November-December 2000.
- [5]. Gopal L, Badrinath SS, Kumar KS, Doshi G, Biswas N. Optic disc in fundus coloboma. *Ophthalmology* 1996; 103: 2120–2127.
- [6]. Olsen TW, Summers CG, Knobloch WH. Predicting visual acuity in children with colobomas involving the optic nerve. *J Pediatr Ophthalmol Strabismus* 1996; 33: 47–51.
- [7]. Hayashi N, Valdes-Dapena M, Green W. CHARGE association: histopathological report of two cases and a review. *J Pediatr Ophthalmol Strabismus*. 1998;35:100-6
- [8]. Chaurasia S, Ramappa M, Sangwan VS. Cataract surgery in eyes with congenital iridolenticular choroidal coloboma. *Br J Ophthalmol*. 2012 Jan;96(1):138-40.

Kouisbahi.A ." Iris and Chorioretinal Coloboma with Bilateral Congenital Cataract: A Case Report." *IOSR Journal of Pharmacy and Biological Sciences (IOSR-JPBS)* 13.4 (2018): 58-59.