

Severe Acne Treatment Based on *Morindacitrifolia* and *Lithobatescatesbeianus* Skin: A Case Report

Dr. Fabiano Peruzzo Schwartz¹, MarialvaGuimarãesBastos²,
Viviane RomãoSoares da Rocha³

¹(Division of Biomedical Engineering, Alfredo Ferreira Filho Institute, Rio de Janeiro, Brazil)
²(Division of Orthomolecular Medicine, Alfredo Ferreira Filho Institute, Rio de Janeiro, Brazil)
³(Division of Pediatrics, Alfredo Ferreira Filho Institute, Rio de Janeiro, Brazil)

Abstract: Acne is not just a cosmetic disorder and is usually reported as a potential generator of considerable physical and psychological scarring. Severe acne requires systemic treatment which mainly include oral antibiotics, hormonal antiandrogens for female patients and oral isotretinoin. Plant-based and animal-based approaches, which are very common in indigenous cultures for treating various types of inflammation, have regained human interests for the treatment of diseases in general. In this sense, the present study reported a case which indicates the potential utility of the combination of *Morindacitrifolia* pulp and *Lithobatescatesbeianus* skin for the improvement of patient skin health and reversion of severe acne. It was prepared a compound to be used on the face skin during four months for the treatment of severe acne. The results revealed a progressive improvement of the inflammatory condition and a significant reduction in the amount of acne. No irritation, allergy or side effects have been observed throughout treatment. It is noteworthy that the progressive improvement was accompanied by the recovery of the patient's self-esteem.

Date of Submission: 18-12-2019

Date of Acceptance: 01-01-2020

I. Introduction

Acne is the most common skin disease¹ and affects nearly all people between the ages of 15 and 17 years². Although it is a benign condition, acne can have considerable morbidity, including pain and discomfort, permanent scarring, and depression and anxiety resulting in poor self-esteem³. Acne is not just a cosmetic disorder and that immune dysfunction plays a role in the development of several comorbidities⁴. Severe acne requires systemic treatment and can be associated with higher prevalence of one or more sinopulmonary, gastrointestinal and psychological comorbid disorders⁴. The available options for severe acne treatment mainly include oral antibiotics, hormonal antiandrogens for female patients and oral isotretinoin⁵. Oral isotretinoin monotherapy is strongly recommended, despite a range of possible serious adverse events that must be considered like inflammatory bowel disease and several ocular symptoms⁵. Alternative treatments for acne have been tested with fewer side effects: the use of Thai medicinal plants with antimicrobial activities showed that 13 medicinal plants could inhibit the growth of acne⁶; the photodynamic therapy with small doses of light was used for improvement of *Propionibacterium acnes* lesions⁷; the essential oil of the Australian native tree *Malaleuca alter – nifolia* had a significant effect in ameliorating the patients' acne by reducing the number of inflamed and non- inflamed lesions⁸.

It is known that, for the last few decades, plant-based medicines have regained human interests in disease treatments^{9,10}. For example, *Morindacitrifolia* (noni) has been widely used as a complementary and alternative therapy with proved beneficial in conditions like skin diseases, several types of cancer, gastritis, respiratory infections, menstrual and urinary tract disorders, fever, diabetes and venereal diseases; its effects are related to its antibacterial, antitumor, anthelmintic, analgesic, anti-inflammatory, immunostimulant properties¹¹. It is also reported that noni has wide range of therapeutic uses in ailments such as arthritis, burns, headache, wounds and skin infections¹².

Animal-based medicines are also important resources for the treatment and relieve of a myriad of illnesses and diseases in practically every human culture, and they have been methodically tested by pharmaceutical companies as sources of drugs to the modern medical science¹³. Some examples are: antimicrobial peptides with potential for development into a therapeutically valuable anti-infective agent was identified in skin secretions and skin extracts of North American frogs¹⁴; the membrane of the natural latex and extract of the *Lithobatescatesbeianus* (bullfrog) skin implanted in cutaneous surgical wounds of Wistar rats promoted an accelerated tissue repair process¹⁵; host-defense peptides from frog skin have potential therapeutic applications as anti-cancer, anti-viral, immunomodulatory, and anti-diabetic agents¹⁶.

Based on these findings and on the constant motivation for finding new methods, this paper reports a case of severe acne treatment using a compound that combines the properties of *Morindacitrifolia* and *Lithobatescatsebeianus* skin.

II. Material And Methods

This experimental study was carried out on a male 16 years old patient of Alfredo Ferreira Filho Institute. It was prepared a compound to be used on the patient face skin during four months for the severe acne treatment.

Compound preparation

The amount of 300 g of farmed bullfrog skin was immersed in 1.5 liter of water and sterilized using a pressure cooker according to the following steps:

- the water was heated to boiling;
- the temperature then was 100 °C and the pressure cooker was steaming;
- after steaming for 10 minutes, the steam valve was closed so that the pressure reached about 2 bar (approx. 2 atmosphere) and the temperature rose to 121 °C;
- the pressure cooker was kept at this pressure and temperature for 15 minutes;
- the heat source was switched off and allowed to cool to 80 °C.

After sterilization, the solution was blended with 300 g of noni's pulp without seeds for about 5 minutes until obtain a smooth and homogeneous mixture. The compound was then refrigerated and stored at 2-8 °C, reaching a consistency similar to gelatin. Under this storage condition, the shelf life of the compound is about 30 days. Figure 1 shows a piece of this compound after refrigeration.



Figure 1.Compound of bullfrog skin and noni.

Procedure methodology

The patient used the compound every night before bed, from August 2019 to November 2019, strictly following the steps bellow:

- wash the face with mild soap and dry it well with a clean towel;
- spread a thin, even layer of compound over the acne-affected region;
- apply extra amount of compound on the most inflamed acnes;
- before bed, wait approximately 10 minutes for the product to dry;
- on waking up, remove all the compound from the face with mild soap.

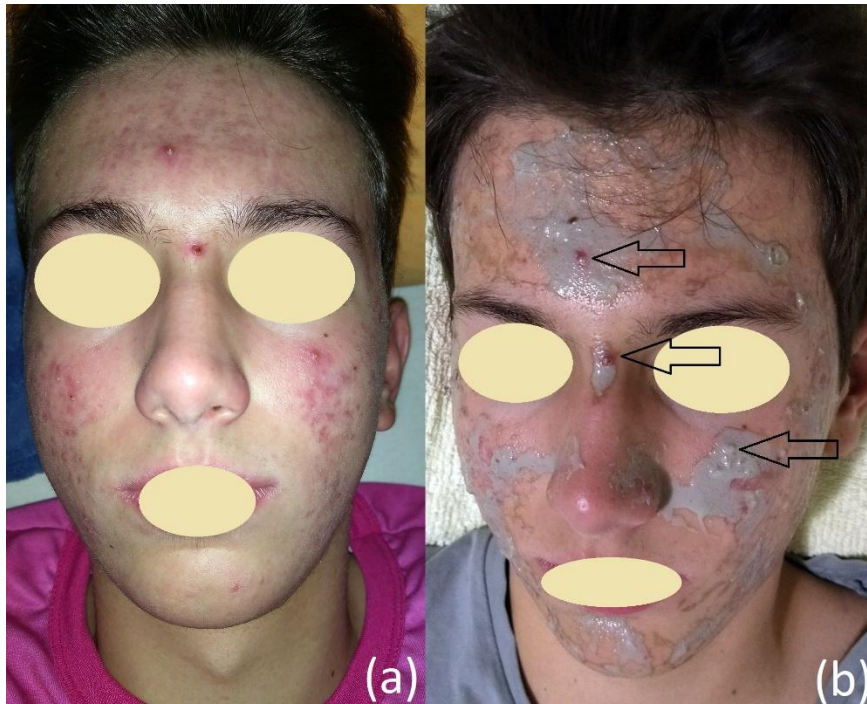

Figure 2. Patient's face (a) before and (b) after the compound application.

Figure 2 shows the patient's face before and after the compound application. Figure 2b shows three arrows pointing to the most inflamed acnes which received an extra amount of the compound to intensify the healing action.

III. Result

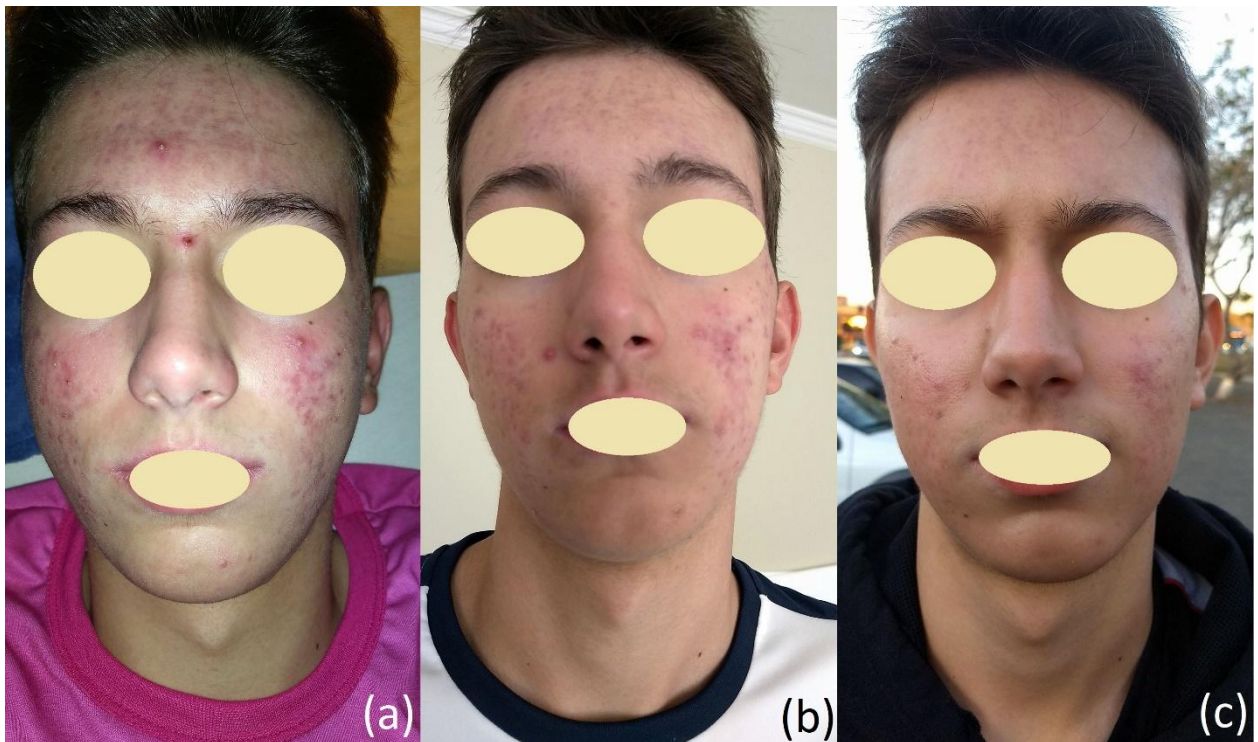


Figure 3. Patient's face throughout treatment: (a) first treatment day; (b) after one month; (c) after two months.

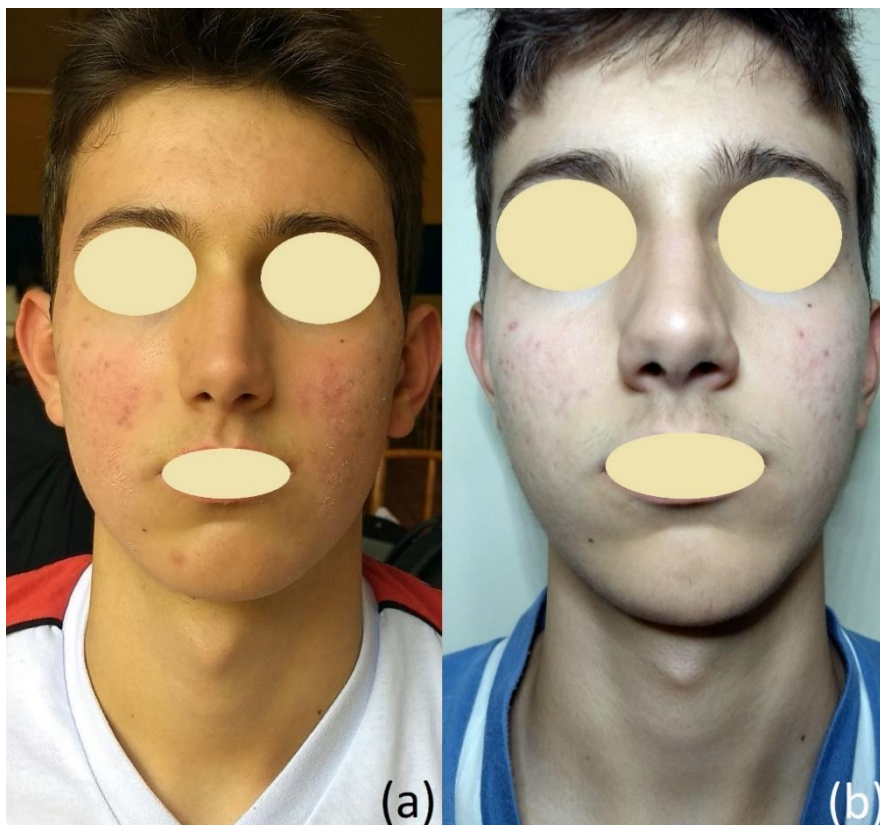


Figure 4. Patient's face throughout treatment: (a) after three months; (b) after four months.

Figures 3 and 4 show the patient's face throughout treatment. The picture in Figure 3a was taken at the August first, immediately before the start of treatment. The other photos correspond to the situation at the end of the first (Figure 3b), second (Figure 3c), third (Figure 4a) and fourth (Figure 4b) month of treatment, respectively.

IV. Discussion

The results presented in figures 3 and 4 show a progressive improvement of the inflammatory condition. Especially on the patient's forehead a significant reduction in the amount of acne can be seen, with almost no incidence of blemishes at the end of treatment. There is also a significant improvement on the cheeks and chin areas, which can be more clearly observed from the end of the second month (Figure 3c).

Some possible explanations are related to the properties of the respective compound's components. Urbán et al. reported that four frog skin-derived antimicrobial peptides (temporin-1DRa, temporin-1Va and the melittin-related peptides AR-23 and RV-23) have relatively high potency against the Gram-positive bacilli *Propionibacterium acnes* which is primarily recognized for its role in acne¹⁷. They also suggest that frog skin peptides may exercise a dual beneficial role in acne treatment by manifesting a bactericidal action on *Propionibacterium acnes* and an anti-inflammatory effect on host cells. Additionally, it is important to consider the bullfrog skin ability in repairing tissues¹⁵.

Noni is also recognized for its anti-inflammatory activity which could improve skin health, increase skin elasticity and firmness, and prevent premature skin aging¹⁸. Noni fruits were widely used by Pacific Islanders to treat skin conditions, such as boils and ulcerated sores^{19,20}. In a clinical trial, noni leaf extracts have been shown to provide protection to the skin against ultraviolet light induced erythema²¹.

The findings reported in literature are consistent with what is seen in figures 3 and 4 where even the most inflamed acnes left no deep scars, in addition to significant improvement in lesion count. Moreover, it should be noted that no irritation, allergy or side effects were observed during treatment, which preliminarily allows to consider as safe and well tolerated the approach used. Another important result concerns the recovery of the patient's self-esteem, who attended classes with shame and discouragement because of severe acne and regained motivation for school activities as improvements occurred throughout treatment.

At first analysis, the results of the present study indicate that the combination of noni and bullfrog skin properties in a single compound associated with continuous systemic treatment for a period of four months were able to reverse severe acne. Based on what has been observed, it is advisable that the treatment be maintained for an equal period, hoping for even better results.

V. Conclusion

The present study reported a case which showed the potential utility of the combination of noni's pulp and bullfrog skin for the improvement of skin health and reversion of severe acne. These results are indicative that noni and bullfrog skin are pharmacologically active and can be exploited in the production of drugs for the treatment of severe acne. However, it is certain that further studies are warranted to determine the real efficacy of this treatment proposal.

References

- [1]. Gollnick HP, Zouboulis CC. Not All Acne Is Acne Vulgaris. *DtschArzteblatt Online*. April 2014. doi:10.3238/arztebl.2014.0301
- [2]. Bhate K, Williams HC. Epidemiology of acne vulgaris. *Br J Dermatol*. 2013;168(3):474-485. doi:10.1111/bjd.12149
- [3]. Roman CJ, Cifu AS, Stein SL. Management of Acne Vulgaris. *JAMA*. 2016;316(13):1402. doi:10.1001/jama.2016.11842
- [4]. Silverberg JI, Silverberg NB. Epidemiology and extracutaneous comorbidities of severe acne in adolescence: a U.S. population-based study. *Br J Dermatol*. 2014;170(5):1136-1142. doi:10.1111/bjd.12912
- [5]. Zouboulis CC, Bettoli V. Management of severe acne. *Br J Dermatol*. 2015;172:27-36. doi:10.1111/bjd.13639
- [6]. Chomnawang MT, Surassmo S, Nukoolkarn VS, Gritsanapan W. Antimicrobial effects of Thai medicinal plants against acne-inducing bacteria. *J Ethnopharmacol*. 2005;101(1-3):330-333. doi:10.1016/j.jep.2005.04.038
- [7]. Hörfelt C, Stenquist B, Larkö O, Faergemann J, Wennberg A. Photodynamic Therapy for Acne Vulgaris: a Pilot Study of the Dose-Response and Mechanism of Action. *Acta Derm Venereol*. 2007;87(4):325-329. doi:10.2340/00015555-0243
- [8]. Bassett IB, Barnetson RSC, Pannowitz DL. A comparative study of tea-tree oil versus benzoylperoxide in the treatment of acne. *Med J Aust*. 1990;153(8):455-458. doi:10.5694/j.1326-5377.1990.tb126150.x
- [9]. Agritasya FC, Husni P, Saptarini N, Levita J. A Systematic Review on the Antioxidant and Antiinflammatory Properties of Zingiberaceae Plants. *IOSR J Pharm Biol Sci*. 2019;14(6):06-10. doi:10.9790/3008-1406030610
- [10]. Natacha A, Christophe C, Melanie A, Alphonse S. Annona Muricata reduced Hepatocytes Differentiation Caused by Cycas revoluta in Wistar Rats. *IOSR J Pharm Biol Sci*. 2019;14(6):06-12. doi:10.9790/3008-1406020612
- [11]. Ali M, Kenganora M, Manjula SN. Health Benefits of Morindacitrifolia (Noni): A Review. *Pharmacogn J*. 2016;8(4):321-334. doi:10.5530/pj.2016.4.4
- [12]. Hirazumi A, Furusawa E, Chou SC, Hokama Y. Immunomodulation contributes to the anticancer activity of morindacitrifolia (noni) fruit juice. *Proc West Pharmacol Soc*. 1996;39:7-9. <http://europepmc.org/abstract/MED/8895953>.
- [13]. Costa-Neto EM. Animal-based medicines: biological prospection and the sustainable use of zootherapeutic resources. *An Acad Bras Cienc*. 2005;77(1):33-43. doi:10.1590/S0001-37652005000100004
- [14]. Conlon JM, Kolodziejek J, Nowotny N. Antimicrobial peptides from the skins of North American frogs. *Biochim Biophys Acta - Biomembr*. 2009;1788(8):1556-1563. doi:10.1016/j.bbmem.2008.09.018
- [15]. Borsari FN, Leal LM, Freitas HMG de, Sasahara TH de C, Machado MRF. Aplicação da membrana de látex natural e do extrato da pele de rã (*Lithobatescatesbiana*) emferidas cirúrgicas cutâneas de ratos Wistar. *Rev Bras Ciência Veterinária*. 2014;21(3):150-155. doi:10.4322/rbcv.2014.375
- [16]. Conlon JM, Mechkarska M, Lukic ML, Flatt PR. Potential therapeutic applications of multifunctional host-defense peptides from frog skin as anti-cancer, anti-viral, immunomodulatory, and anti-diabetic agents. *Peptides*. 2014;57:67-77. doi:10.1016/j.peptides.2014.04.019
- [17]. Urbán E, Nagy E, Pál T, Sonnevend Á, Conlon JM. Activities of four frog skin-derived antimicrobial peptides (temporin-1DRa, temporin-1Va and the melittin-related peptides AR-23 and RV-23) against anaerobic bacteria. *Int J Antimicrob Agents*. 2007;29(3):317-321. doi:10.1016/j.ijantimicag.2006.09.007
- [18]. West BJ, Sabin RA. Efficacy of a Morindacitrifolia Based Skin Care Regimen. *Curr Res J Biol Sci*. 2012;4(3):310-314.
- [19]. Whistler WA. *Polynesian Herbal Medicine*. Lawai, Kauai, Hawaii: National Tropical Botanical Garden; 1992.
- [20]. Weiner MA. *Secrets of Fijian Medicine*. Berkeley, California: University of California; 1970.
- [21]. West BJ, Deng S, Palu AK, Jensen CJ. Morindacitrifolia Linn. (Rubiaceae) leaf extracts mitigate UVB-induced erythema. *J Nat Med*. 2009;63(3):351-354. doi:10.1007/s11418-009-0327-7

Dr. Fabiano Peruzzo Schwartz. "Severe Acne Treatment Based on Morindacitrifolia and Lithobatescatesbeianus Skin: A Case Report." *IOSR Journal of Pharmacy and Biological Sciences (IOSR-JPBS)* 14.6 (2019): 55-59