

“Carotid body tumour: A case report”

Ganesh Chandra Gayen¹, Atanu Kumar Das², Ritam Ray³

Assistant professor, Dept. of ENT, Burdwan Medical College & Hospital, P.O. – Rajbati, Burdwan – 713104,
West Bengal, India

Postgraduate Student, Dept. of ENT, Burdwan Medical College & Hospital, P.O. – Rajbati, Burdwan –
713104, West Bengal, India

RMO-cum-clinical tutor, Dept. of ENT, Burdwan Medical College & Hospital, P.O. – Rajbati, Burdwan –
713104, West Bengal, India

Abstract: Carotid body tumours are rare, slowly growing benign neoplasm arising from paraganglionic cells at the region of carotid bifurcation. They are the rare tumours of head and neck region derived from neural crest. We report here a case of carotid body tumour which was successfully treated surgically.

Key Word: Carotid body tumour ; Paraganglioma ; Chemodectoma

I. Introduction

Carotid body tumour is a rare benign paraganglioma which present as neck swelling. Because of its rarity we sometimes misdiagnose it as other disease. It is also known as chemodectoma. It is a highly vascular tumour and arises from the carotid bifurcation. it has a autosomal dominant inheritance pattern with incomplete penetrance.

II. Case Report

A 25 years female presented to the department of ENT of our institution with Painless slowly growing swelling in the right side of upper part of neck for 2 years. There was no pressure symptoms and no history of swelling elsewhere in the body. No past history of tuberculosis and no family history of such swelling was there.

On examination, an oval, around 6 X 4 cm swelling was present in the right side upper part of neck just below and behind the angle of mandible. On palpation, it was non tender, smooth surface, firm in consistency, pulsatile and more mobile transversely than vertically. No regional lymphadenopathy was there.

Routine blood examination, stool and urine examination were within normal limits. FNAC revealed hamartoma. CT Scan (Fig. I) revealed a well defined avidly enhancing isodense mass in right carotid space which displaced the great vessels posterolaterally.

Under GA, neck was explored by a transverse cervical incision at the level of hyoid bone. The mass was medial to carotid bifurcation extending from transverse process of cervical vertebra to mastoid process on the right side. The mass was excised after ligation of external carotid artery keeping internal carotid artery intact. Histopathology (Fig. II) revealed Zellballens with a prominent fibrovascular connective tissue stroma suggestive of carotid body tumour. Postoperative period was uneventful. Patient had no recurrence after 2 years follow up.

III. Discussion

Carotid body tumour are usually benign lesions first mentioned in 1743 by Von Haller and actually described in 1862 by Lushka [1]. The carotid body itself is a small chemoreceptor organ buried posteriorly in the adventitia of the common carotid bifurcation and have a chemoreceptor role by modulating respiratory and cardiovascular function in response to fluctuations in arterial pH, O₂, and CO₂. Neoplastic growth of this area is known as chemodectomas or paragangliomas.

Incidence of carotid body tumour is only 0.012% [2]. They can be unilateral or bilateral (7%). In approximately 10% a familial trend exists [3]. Familial cases inherited with an autosomal dominant inheritance pattern with incomplete penetrance. There is female gender predominance noted 8.3:1 at high altitudes as compared to a modest one of 2:1 in lower altitudes [4]. The average age of presentation is between 35 to 50 years. Increased prevalence is also associated with high altitudes. 10% of cases are multicentric.

Carotid body tumour is the most common type of paraganglioma and usually presents as an asymptomatic mass in the anterolateral region of the neck. Pressure symptoms may develop with

increasing size of the mass. On physical examination, this tumour is laterally mobile but vertically fixed because of its attachment to the carotid bifurcation [5]. Mass is frequently pulsatile and a bruit may be auscultated over the mass. The large majority of carotid paragangliomas are non-secreting but enquiry must be made about any symptoms of excessive catecholamine secretion like uncontrolled hypertension, tachycardia, facial flushing or excessive sweating.

Majority of carotid body tumours are benign, but may infiltrate locally. About 3% are malignant [6]. The commonest overt malignant manifestation is local recurrence. It grows slowly and rarely metastasizes.

The investigation of choice is bilateral angiography [7] where the tumour appears as a hypervascular oval mass. It substantiates the diagnosis, indicates the size and vascularity of the tumour and determines bilaterality [8,9]. On sonography, paraganglioma present as a well-defined, solid hypoechoic mass and on colour Doppler imaging, hypervascularity with a low-resistance flow pattern is seen [10]. Colour Doppler and angiography are crucial in showing vascularisation details of the tumour [11]. Computed tomography and magnetic resonance imaging reveal a well circumscribed mass at or above the carotid bifurcation, which splay the internal and external carotid arteries. On post contrast scan there is intense enhancement [12,13]. The mass usually shows a salt and pepper appearance caused by vessels with signal void within the tumour stroma.

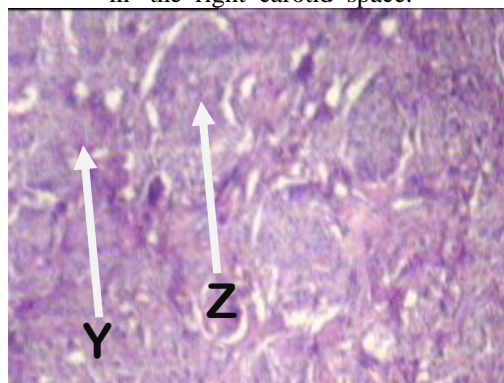
Fine-needle aspiration has a beneficial role in the diagnosis of carotid body tumour [14]. Paragangliomas consist of clusters of Type I or chief cells and Type II or sustentacular cells. These clusters of cells make up the histologic structure termed Zellballen. Nuclear pleomorphism and cellular hyperchromatism is common in paragangliomas. Malignancy cannot be determined histologically but is reserved for presence of clinical evidences like local, regional, or distant metastasis.

Tissue diagnosis is not necessary and biopsy may be dangerous[15]. Once diagnosed, excision with subadventitial dissection is the treatment of choice. In inoperable cases radiation therapy is recommended [16].

IV. Figures

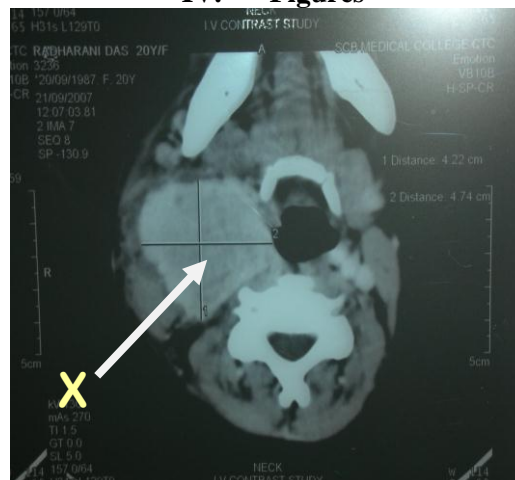

Figure I : CT Scan (axial view) of neck showing a well-defined avidly enhancing isodense mass (X) in the right carotid space.



(10x10)

Haematoxilin & Eosin stain

Figure II : Photomicrography showing Zellballens (Y) with a prominent fibrovascular connective tissue stroma (Z).

References

- [1]. Peterson EW, Meeker LH. Tumours of the carotid body. *Ann Surg* 1936; 103: 554- 567.
- [2]. Lack et al. paragangliomas of the head & neck region : a clinical study, *cancer* 39:556-557, 1977
- [3]. Wang D, Barros AAB, Johnston CF, Buchanan KD. Oncogene expression in Carotid Body Tumour. *Cancer* 1996; 77(12): 2581-2587.
- [4]. Rodriguez -Cuevas S, Lopez-Garza J, Labastida-Almendares S. Carotid BodyTumour in inhabitants of altitudes higher than 2000 metres above sea level. *Head & Neck* 1998; 20(5): 374-378
- [5]. Razakaboay M, Maillefert JF, Wendling D, et al. Bone metastases from a paraganglioma. A review of five cases. *Rev Rhum Engl Ed.* 1999; 66: 86-91.
- [6]. Batsakis, J.G. : "Tumours of Head of Neck", Williams and Wilkins Co., Baltimore, 1974, Chapter 19, pp. 280-287
- [7]. Rush BF Jr. Current concepts in treatment of carotid body tumours. *Surg* 1962; 692.
- [8]. Chambers, R. G. and Mahoney, W. D.: Carotid body tumours, *Amer. J. Surg.* 116: 554-558, 1968.
- [9]. Conley, J. M.: Management of carotid body tumours. *Surg., Gynec. and Obstet.*, 117: 722-732, 1963.
- [10]. Jansen JC, Baatenburg de Jong RJ, Schipper J. Color- Doppler imaging of paragangliomas in the neck. *J Clin Ultrasound.* 1997; 25: 481-5.
- [11]. Muhm M, Pelteratuer P, Gstottner W. Diagnostic and therapeutic approaches to carotid body tumors. Review of 24 patients. *Arch Surg.* 1997; 132: 279-84.
- [12]. Zidi A, Bouaziz N, Mnif N, Kribi L, Kara M, Salah M, Ferjaoui M, Hamza R. Carotid body tumors: contribution of the various imaging techniques. A report of six cases. *J Rediol* 2000 Sep ; 81 (9) : 953-7.
- [13]. Van den Berg R, Van Gils AP, Wasser MN. Imaging of head and neck paragangliomas with three-dimensional time-of-flight MR angiography. *AJR Am J Roentgenol* 1999 Jun; 172 (6) : 1667-73.
- [14]. Das DK, Gupta AK, Chowdhury V, et al. Fine-needle aspiration diagnosis of carotid body tumor: report of a case and review of experience with cytologic features in four cases. *Diagn Cytopathol.* 1997; 17: 143-7.
- [15]. Harwell, W. : Carotid body tumours, *Surgery.*, 59:483-493, 1966.
- [16]. Howell, A., Monasterio, J. and Stuteville, O., Chemodectomas of the head and neck, *Surg. Clin. North. Amer.*, 53: 175-177, 1973

ABBREVIATIONS

- FNAC - Fine needle aspiration cytology.
CT - Computed tomography.
GA - General anaesthesia.
CTVS - Cardiothoracic vascular surgeon.
pH - Power of hydrogen.
O₂ - Oxygen.
Co₂ - Carbon di-oxide.